Grand Rounds

Renal Artery Disease:

Diagnosis and Management

JEFFREY W. OLIN, D.O.

Abstract

Renal artery stenosis (RAS) is most commonly due to either fibromuscular dysplasia or atherosclerosis. The former predominates in young women while atherosclerosis is usually encountered in individuals over the age of 55. The most common clinical manifestation of fibromuscular dysplasia is hypertension, which can frequently be cured or significantly improved with percutaneous balloon dilation. Atherosclerotic RAS may present with hypertension, renal failure (ischemic nephropathy), recurrent episodes of congestive heart failure and flash pulmonary edema or may be discovered incidentally during an imaging procedure for some other reason.

Screening tests for RAS have improved considerably over the last decade. While captopril renography was utilized almost exclusively in the past, duplex ultrasound of the renal arteries or magnetic resonance angiography has replaced other modalities as the screening test of choice in many centers. Rarely does an arteriogram have to be performed for diagnostic purposes only.

Management of RAS consists of three possible strategies: medical management, surgical management or percutaneous therapy with balloon angioplasty and stent implantation. The treatment of choice to control hypertension in patients with fibromuscular disease is percutaneous angioplasty. Renal artery stenting has replaced surgical revascularization for most patients with atherosclerotic disease who meet the criteria for intervention.

Key Words: Renal artery disease, diagnosis, treatment.

OVER THE LAST DECADE, there has been increased awareness of renovascular disease as a potentially correctable cause of hypertension and renal insufficiency. The association between renal artery stenosis (RAS), coronary artery disease and congestive heart failure (CHF) has been well studied. It is known that there is a markedly decreased survival rate (due to myocardial infarction and stroke) in patients with RAS. Nephrologists have long recognized that RAS may present with acute or chronic renal failure (ischemic nephropathy), at times leading to end-stage renal disease. Because RAS may present with many different clinical manifestations, primary care physicians, cardiovascular specialists, vascular surgeons and nephrologists will encounter RAS with increased frequency.

Director, Vascular Medicine, Zena and Michael A. Wiener Cardiovascular Institute, Mount Sinai School of Medicine, New York, NY.

Address all correspondence to Jeffrey W. Olin, D.O., Zena and Michael A. Wiener Cardiovascular Institute, Box 1033, Mount Sinai School of Medicine, One East 100th Street, New York, NY 10029; E-mail: jeffrey.olin@msnyuhealth.org

Based on a Grand Rounds presentation of the Cardiovascular Institute, Mount Sinai School of Medicine, New York, NY on September 30, 2002, and updated as of March 2003.

Incidentally discovered RAS is quite common (1, 2), but renovascular hypertension only occurs in 1–5% of all patients with hypertension. RAS is most commonly due to either fibromuscular dysplasia (FMD) or atherosclerosis. The predominant clinical manifestation of FMD is hypertension that can frequently be cured or significantly improved with percutaneous transluminal angioplasty. FMD predominates in young women, while atherosclerosis is encountered most often in individuals over the age of 55. Approximately 90% of all renovascular lesions are secondary to atherosclerosis (3). Atherosclerotic RAS most often occurs at the ostium or the proximal 2 cm of the renal artery (4). Distal arterial or branch involvement is distinctly uncommon. Atherosclerotic RAS may present with one or more of the following: hypertension, renal failure (ischemic nephropathy), refractory angina, and/or recurrent episodes of CHF and flash pulmonary edema.

Dustan et al. (5) reviewed 149 aortograms and found that approximately half of the patients with greater than 50% RAS did not have hypertension. Moreover, the presence of anatomic RAS does not necessarily establish that the hypertension or renal failure is caused

by the RAS. Primary (essential) hypertension may exist for years prior to the development of atherosclerotic RAS later in life. Renal revascularization (percutaneous transluminal angioplasty [PTA]/stent, surgery) may result in improvement of blood pressure control in 50–80% of patients but cure is unusual in patients with longstanding hypertension (4, 6–9). Ischemic nephropathy or flash pulmonary edema almost always occurs in the presence of bilateral renal artery disease or disease in a solitary functioning kidney. Percutaneous or surgical revascularization can lead to improvement or stabilization in renal function and improvement in CHF in the carefully selected patient (8–10).

Pathogenesis of Hypertension in Renal Artery Stenosis

A detailed description of the pathophysiological mechanisms of hypertension in RAS is beyond the scope of this article. On a very simplistic level, early in the course of the disease, patients with unilateral renal artery stenosis have a renin-mediated form of hypertension, while patients with bilateral RAS, or stenosis to a solitary functioning kidney, have a volume-mediated form of hypertension (9, 11). In patients who are volume expanded, administration of either an angiotensin-converting enzyme inhibitor (ACEI) or angiotensin receptor blocker (ARB) does not cause a decrease in blood pressure or change in renal blood flow. Functional renal insufficiency may even occur when ACEIs are administered to patients with bilateral RAS or RAS to a solitary kidney, especially in the volume contracted state. However, dietary restriction of sodium or administration of diuretics will return the subject to a renin-mediated form of hypertension, and restore sensitivity to an ACEI or ARB.

Pathophysiology of Ischemic Nephropathy

It is difficult to fully understand the nature of ischemic nephropathy. This is due to several factors: (a) there is no linear relationship between the degree of renal artery stenosis and the degree of renal dysfunction (11); (b) it is not easy to determine with certainty whether stenosis of the main renal artery is causing the renal insufficiency or whether parenchymal disease is the culprit; and (c) some patients undergoing renal revascularization (PTA/stent/surgery) demonstrate worsening renal function after the procedure. This may be due to atheromatous embolization caused by the procedure, or to the natural history of the underlying disease that caused the problem in the first place. It should be emphasized that patients who develop azotemia while receiving angiotensin-converting enzyme inhibitors or ARBs have bilateral RAS, RAS to a solitary kidney, or decompensated CHF in the sodium-depleted state (12–17).

There are two mechanisms by which renal functional impairment may occur with the use of antihypertensive agents. The first mechanism can be caused by any antihypertensive agent, when a critical perfusion pressure is reached below which the kidney no longer receives adequate perfusion. This has been shown by the infusion of sodium nitroprusside in patients with high-grade bilateral RAS (13). When the critical perfusion pressure was reached, the urine output, renal blood flow, and glomerular filtration rate declined and later returned to normal when the blood pressure increased above this critical perfusion pressure. The exact pressure necessary to perfuse a kidney with RAS varies with the degree of stenosis and is different in different patients.

The second mechanism is confined to patients receiving ACEI or ARB agents and may or may not involve significant change in blood pressure (12, 14). Patients with high-grade bilateral RAS or RAS to a solitary kidney may be highly dependent on angiotensin II for glomerular filtration. This is particularly common in patients who receive a combination of ACE inhibitor and diuretic (18), or in patients who are placed on a sodium-restricted diet (19). Under these circumstances, the constrictive effect of angiotensin II on the efferent arteriole allows for the maintenance of normal transglomerular capillary hydraulic pressure, thus allowing glomerular filtration to remain normal in the presence of markedly diminished blood flow. In this instance, glomerular filtration is highly dependent on angiotensin II. When an ACEI is administered, the efferent arteriolar tone is no longer maintained and glomerular filtration is therefore decreased. A similar situation occurs in patients with decompensated CHF who are sodium depleted (16).

Clinical Manifestations of Renal Artery Disease

Prevalence

In a recent population-based study, Hansen and colleagues have reported on the prevalence of renovascular disease in a cohort of 834 el-

derly patients (20), participants of the Cardiovascular Health Study, who underwent renal duplex ultrasound. Fifty-seven (6.8%) had anatomic renal artery stenosis. There was no difference in the prevalence of RAS in whites (6.9%) compared to African Americans (6.7%).

Several series have looked at the prevalence of renovascular disease in patients who have atherosclerotic disease elsewhere. To determine the prevalence of atherosclerotic RAS, we studied 395 consecutive patients who had undergone arteriography as part of an evaluation for an abdominal aortic aneurysm, aortoiliac occlusive disease, and peripheral arterial disease (Table 1) (1). These patients did not have the usual clinical clues to suggest RAS. High-grade bilateral renal artery disease was present in approximately 13% of the patients. In the 319 patients reported in 6 different studies, 44% had bilateral RAS (8). Other studies have shown that 22–59% of patients with peripheral arterial disease have significant RAS (21).

It has also been established that RAS is common in patients with coronary artery disease. Of 7,758 patients undergoing cardiac catheterization during a 78-month period, 3,987 underwent aortography to screen for RAS at the time of catheterization (22). One hundred ninety-one (4.8%) subjects had greater than 75% stenosis of the renal artery. Severe bilateral disease occurred in 0.8%. In the Mayo Clinic series (23), renal arteries were studied at the time of cardiac catheterization in patients with hypertension. Ninety percent of the renal arteries were adequately visualized and no complications occurred from the aortogram. Greater than 50% stenosis of the renal artery was present in 19.2%. Greater than 70% stenosis occurred in 7%. Bilateral RAS was present in 3.7% of patients.

Natural History

Knowledge of the natural history is extremely important in the subsequent management of patients with RAS. Most natural history studies reported in the literature were retrospective studies. The rates of progression ranged from 36–71% (24). In Schreiber's series (24), only 16% of patients progressed to total occlusion over a mean follow-up of 52 months. However, the rate of progression to total occlusion occurred more frequently (39%) when there was a stenosis greater than 75% on the initial renal arteriogram.

Zierler et al. (25) utilized renal duplex ultrasound to prospectively study anatomic progression of atherosclerotic renovascular disease. If the renal arteries were normal, only 8% progressed over a 36-month period. However, at 3 years, 48% of patients progressed from less than 60% stenosis to 60% or greater stenosis. All four renal arteries that progressed to occlusion had greater than 60% stenosis at the initial visit. Progression of RAS occurred at an average rate of 7% per year for all categories of baseline disease combined.

The effect of RAS on kidney size has been well studied (26). Using duplex ultrasound, Caps and colleagues prospectively followed 204 kidneys in 122 patients with known renal artery stenosis for a mean of 33 months. The cumulative incidence of renal atrophy was 5.5% in those kidneys considered to have no renal artery disease, while renal atrophy occurred in those kidneys in which the RAS was less than 60%. Renal atrophy occurred in 20.8% of those kidneys in which the RAS exceeded 60% (p=0.009, log rank test).

There are no good data to assess the prevalence of end-stage renal disease (ESRD) caused by renal artery stenosis. Scoble et al. (27) found

TABLE 1
Prevalence of Atherosclerotic Renal Artery Stenosis

> 50% stenosis	Abdominal Aortic Aneurysm (n=109)	Aortoiliac Occlusive Disease (n=21)	Peripheral Arterial Disease (n=189)	Renal Artery Stenosis (n=76)
All patients	41 (38%)	7 (33%)	74 (39%)	53 (70%)*
Diabetic patients	6 (50%)	1 (33%)	34 (50%)**	10 (71%)
Nondiabetic patients	35 (36%)	6 (33%)	40 (33%)	43 (69%)

** p<0.001
** p<0.02

Reproduced with permission from Olin JW, Melia M, Young JR, et al. Prevalence of atherosclerotic renal artery stenosis in patients with atherosclerosis elsewhere. Am J Med 1990; 88:46N–51N (1).

that atherosclerotic renovascular disease was the cause of ESRD in 14% of patients starting dialysis therapy. Mailloux and colleagues (28) reviewed the causes of ESRD in 683 patients over a 20-year period. Eighty-three patients (12%) had documented RAS as a cause of ESRD. Patients receiving dialysis due to renal artery disease had a much poorer prognosis than patients with ESRD due to other causes (Table 2) (28).

The mere presence of RAS, even prior to developing ESRD, portends a poor prognosis. Patient survival decreases as the severity of RAS increases, with 2-year survival rates of 96% for patients with unilateral RAS, 74% for patients with bilateral RAS, and 47% in patients with stenosis or occlusion to a solitary functioning kidney (29).

TABLE 3
Clinical Clues to the Diagnosis of Atherosclerotic Renal Artery Stenosis

- Onset of hypertension after the age of 55
- Exacerbation of previously well-controlled hypertension
- Malignant hypertension
- Resistant hypertension
- Epigastric bruit (systolic/diastolic)
- Unexplained azotemia
- Azotemia while receiving angiotensin-converting enzyme inhibitors or angiotensin receptor blocking agents
- Atrophic kidney or discrepancy in size between the two kidneys
- Recurrent congestive heart failure or "flash" pulmonary edema
- Atherosclerosis elsewhere

Clues to the Diagnosis of Renal Artery Stenosis

Most patients with atherosclerotic RAS have one or more of the clinical clues listed in Table 3.

Individuals who develop hypertension between the ages of 30 and 55 usually have primary (essential) hypertension. If the initial diagnosis of hypertension is made before the age of 30, it may be due to FMD. Since atherosclerosis occurs in older individuals, it is usually the cause of RAS after the age of 55. Accelerated or malignant hypertension has also been associated with a very high prevalence of RAS. "Resistant hypertension" is defined as failure to normalize blood pressure to less than 140/90 mm Hg (30) following a trial consisting of at least three drugs with different mechanisms of action. The diagnosis of renovascular disease should be strongly considered in patients with resistant hypertension.

Gifford et al. (31) found that 71% of patients (53 of 75 patients) with an atrophic kidney had severe stenosis or complete occlusion of the renal artery ipsilateral to the small kidney. Three studies have shown that if there is a discrepancy in size between the two kidneys or if one kidney is atrophic, there is a 60% chance that the contralateral renal artery (normal-sized kidney) is severely stenotic (9). Therefore, the presence of an atrophic kidney or a discrepancy in size between the two kidneys demands a thorough investigation for the presence of renovascular disease. Likewise, patients who develop azotemia while receiving an ACE inhibitor or ARB should be investigated for the presence of RAS (13–16).

Recurrent CHF and "flash" pulmonary edema not related to active ischemic heart disease can result from bilateral RAS (or unilateral RAS to a single functioning kidney). This is probably related to undue volume expansion. The use of ACEI or ARB by these patients with high-grade bilateral disease may be contraindicated (9).

TABLE 2
Survival Estimates for Selected Renal Diagnoses on Dialysis

Diagnosis	Median Survival	Length of Survival			
		2 year	5 year	10 year	15 year
Polycystic kidney disease (n=56)	133 months	91%	77%	59%	32%
Malignant hypertension (n=23)	55 months	77%	25%	0	0
Renal vascular disease (n=83)	25 months	56%	18%	5%	0

Reproduced with permission from Mailloux LU, Napolitano B, Bellucci AG, et al. Renal vascular disease causing end-stage renal disease, incidence, clinical correlates, and outcomes: a 20-year clinical experience. Am J Kidney Dis 1994; 24:622–629 (28).

Diagnosis of Renovascular Disease

The ideal imaging procedure for RAS should: (a) identify the main renal arteries as well as accessory vessels; (b) localize the site of stenosis or disease; (c) provide evidence for the hemodynamic significance of the lesion; and (d) identify associated pathology (e.g., abdominal aortic aneurysm, renal mass, etc.) that may have an impact on the treatment of the renal artery disease (32, 33).

Angiography, once considered the "gold standard" for arterial imaging, is rarely required to make the diagnosis of RAS. Usually one or more of the noninvasive modalities can accurately assess the renal arteries. Exceptions to this general rule may occur in patients with FMD or renal artery aneurysms, where there may be branch involvement. Pressure gradients should also be obtained, to confirm the physiological significance of a given lesion. CO_2 and gadolinium angiography are non-nephrotoxic contrast agents that may be particularly useful in patients with renal insufficiency.

Renal Arteriography at the Time of Cardiac Catheterization

Since RAS is common in patients with coronary artery disease, some cardiologists perform an aortogram on the "way out" after performing a cardiac catheterization (2, 34). This is a hotly debated issue at the present time. We should have some guidance of the advisability of renal angiography at the time of cardiac catheterization when the ACC/AHA Guidelines for the Management of Patients with Peripheral (and renal) Arterial Disease are published within the next year. If the patient meets clinical criteria for intervention (see below) it is advisable to perform an abdominal aortogram at the time of the catheterization. We are opposed to the stenting of an RAS just because a stenosis is found (35).

Duplex Ultrasonography

Duplex ultrasonography is an excellent test for detecting RAS (Fig. 1). It is the least expensive of the imaging modalities and provides useful information about the degree of stenosis, the kidney size, and other associated disease processes such as aneurysms or obstruction. Duplex may also help predict which patients will demonstrate an improvement in blood pressure control or renal function after renal artery angioplasty and stenting (36).

Duplex ultrasonography combines B-mode ultrasound and Doppler examination. In the longitudinal (long axis) view, the peak systolic flow velocity in the aorta is recorded at the level of the renal arteries. The aortic velocity and the highest renal artery peak systolic velocity are used to calculate the renal aortic ratio. This technique is discussed in detail in several reviews (9, 32, 37). Overall, when compared to angiography, duplex ultrasound has a sensitivity and specificity of 84–98% and 62–99% respectively when used to diagnose RAS (32). We performed a prospective study comparing duplex ultrasound to angiography (Table 4) (37). If the end diastolic velocity was greater than 150 cm/sec, then the degree of stenosis was likely to be greater than 80%.

It is very important to measure the resistive index during the renal artery duplex examination. A Doppler waveform is obtained from the parenchyma of the kidney. The resistive index is calculated by the formula:

$$\frac{PSV - EDV}{PSV}$$

where PSV = peak systolic velocity
and EDV = end diastolic velocity

A recent study used Doppler ultrasonography to predict the outcome of therapy in patients with RAS (36), 97% of patients with resistance index greater than 80 demonstrated no improvement in blood pressure and 80% had no improvement in renal function. The authors suggest that the increased resistive index is an indication of structural abnormalities in the small blood vessels of the kidney. Such small vessel disease has been seen with longstanding hypertension associated with nephrosclerosis or glomerulosclerosis. If these results are confirmed, it could provide a method for predicting which patients will improve after percutaneous intervention.

Renal artery duplex is an excellent test for the follow-up of RAS after percutaneous therapy or surgical bypass (Fig. 1C). Unlike magnetic resonance angiography (which may be affected by artifact or scatter produced by the stent), ultrasound transmission through the stent is not a problem.

Magnetic Resonance Angiography

Magnetic resonance angiography (MRA) provides excellent imaging of the abdominal vasculature and associated anatomical struc-

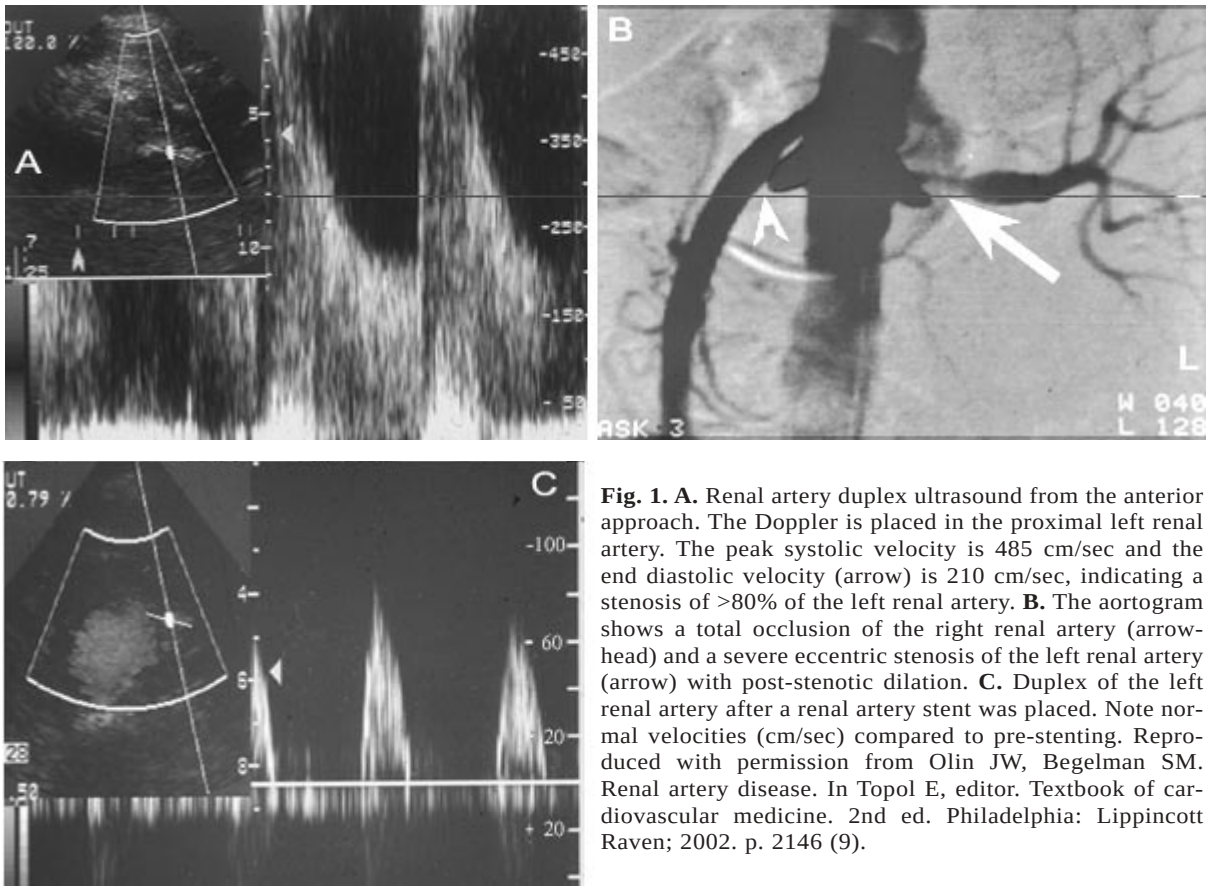

Fig. 1. A. Renal artery duplex ultrasound from the anterior approach. The Doppler is placed in the proximal left renal artery. The peak systolic velocity is 485 cm/sec and the end diastolic velocity (arrow) is 210 cm/sec, indicating a stenosis of >80% of the left renal artery. **B.** The aortogram shows a total occlusion of the right renal artery (arrowhead) and a severe eccentric stenosis of the left renal artery (arrow) with post-stenotic dilation. **C.** Duplex of the left renal artery after a renal artery stent was placed. Note normal velocities (cm/sec) compared to pre-stenting. Reproduced with permission from Olin JW, Begelman SM. Renal artery disease. In Topol E, editor. Textbook of cardiovascular medicine. 2nd ed. Philadelphia: Lippincott Raven; 2002. p. 2146 (9).

TABLE 4
Comparison of Duplex Ultrasound with Arteriography

Stenosis by Ultrasound	Stenosis by Arteriography 0–59%	60–79%	80–99%	100%	Total
0–59%	62	0	1	1	64
60–99%	1	31	67	0	99
100%	0	1	1	22	24
Total	63	32	69	23	187

Sensitivity	0.98
Specificity	0.98
Positive predictive value	0.99
Negative predictive value	0.97

Reproduced with permission from Olin JW, Piedmonte MR, Young JR, et al. The utility of duplex ultrasound scanning of the renal arteries for diagnosing significant renal artery stenosis. Ann Intern Med 1995; 122:833–838 (37).

tures. Contrast-enhanced MRA provides a superior quality study when compared to noncontrast studies. Gadolinium chelate is the contrast agent of choice, but other contrast agents, which are under development, may improve the current imaging techniques. Unlike ionic and non-ionic iodinated contrast agents, gadolinium is not nephrotoxic and can be used safely in patients with renal insufficiency. The imaging time is substantially shortened, and 20–40 second acquisition times are not uncommon. This eliminates some artifact created by gross patient movement (32, 38). When compared to angiography, MRA has demonstrated a sensitivity of

90–100% and a specificity of 76–94% (32, 38–40). A recent meta-analysis was performed with 499 patients who underwent a gadolinium-enhanced MRA and catheter angiography within 3 months of one another. The sensitivity and specificity of MRA were 97% and 93% respectively. MRA accurately identified accessory renal arteries 82% of the time (41). However, MRA does not have the same sensitivity and specificity for patients with FMD.

CT Angiography

Computed tomography (CT) angiography is another strategy for the diagnosis of RAS. The sensitivity and specificity are good; however, it requires a large bolus of contrast, thus making it a less attractive diagnostic strategy in the azotemic patient. However, with the advent of multi-detector 16 row CT scanners, one can get clearer images in a shorter period of time and with less contrast. This technique is gaining in popularity for the evaluation of renal artery stenosis.

Captopril Renography

Radionuclide imaging techniques provide a noninvasive and safe way to evaluate renal blood flow and excretory function. When an ACE inhibitor such as captopril is added to isotope renography, the sensitivity and specificity of the test improve considerably, especially for patients with unilateral RAS. In most instances of unilateral RAS, the glomerular filtration rate of the stenotic kidney falls by approximately 30% after captopril administration (42). In contrast, the contralateral normal kidney exhibits an increase in glomerular filtration rate, urine flow and salt excretion despite a reduction in systemic blood pressure. These expected physiologic changes within the stenotic and contralateral kidneys are the basis of the asymmetry of renal function following ACE inhibition detected by renal scintigraphy.

Overall, the accuracy of captopril renography in identifying patients with renovascular disease appears quite acceptable, with a sensitivity of about 85–90% (range 45–94) and specificity of about 93–98% (range 81–100). Those patients with unilateral disease and normal renal function would be best suited for a captopril renogram. The presence of significant azotemia or bilateral RAS may adversely affect the accuracy of captopril renography. Many investigators have excluded patients with serum creatinine exceeding 2.5–3.0 mg/dL.

While the captopril renogram was once the noninvasive diagnostic test of choice for patients with RAS, it is now relegated to a secondary screening modality, since the quality of the images of duplex ultrasound, MRA, and CT angiography are so good.

Renal Vein Renin

Renal vein renin measurement is not a useful test to screen for RAS (9). In addition, it rarely adds value in determining who will benefit from therapy. Except under unusual circumstances, we do not use this as a diagnostic test. One useful diagnostic algorithm is shown in Fig. 2 (43).

Management of Renal Artery Disease

Prior to 1990, if a patient met the criteria for intervention, surgical renal artery revascularization was usually performed. However, since the introduction of stents, surgical revascularization is rarely performed solely for the treatment of renal artery disease. Despite advances in the technical aspects of angioplasty and stent implantation, there is a paucity of controlled clinical trials assessing the role of renal artery angioplasty and stenting to control hypertension or to preserve renal function. Controversy still exists as to the value of renal artery stenting and the appropriate indications for this procedure. The indications for PTA/stent implantation for atherosclerotic RAS include at least a 70% stenosis of one or both renal arteries and at least one of the following:

- Inability to adequately control the blood pressure despite a good antihypertensive regimen.
- Chronic renal insufficiency not related to another clear-cut cause (disease should be bilateral or stenosis to a solitary functioning kidney). The treatment of an elevated serum creatinine with unilateral disease is controversial, and there are no good clinical trials to help guide the clinician (44).
- Dialysis-dependent renal failure in a patient without another definite cause of ESRD (45–47).
- Recurrent CHF or “flash” pulmonary edema not attributable to active ischemia (10, 48–50).

Medical Therapy

All patients with hypertension should be treated medically, even if they undergo other

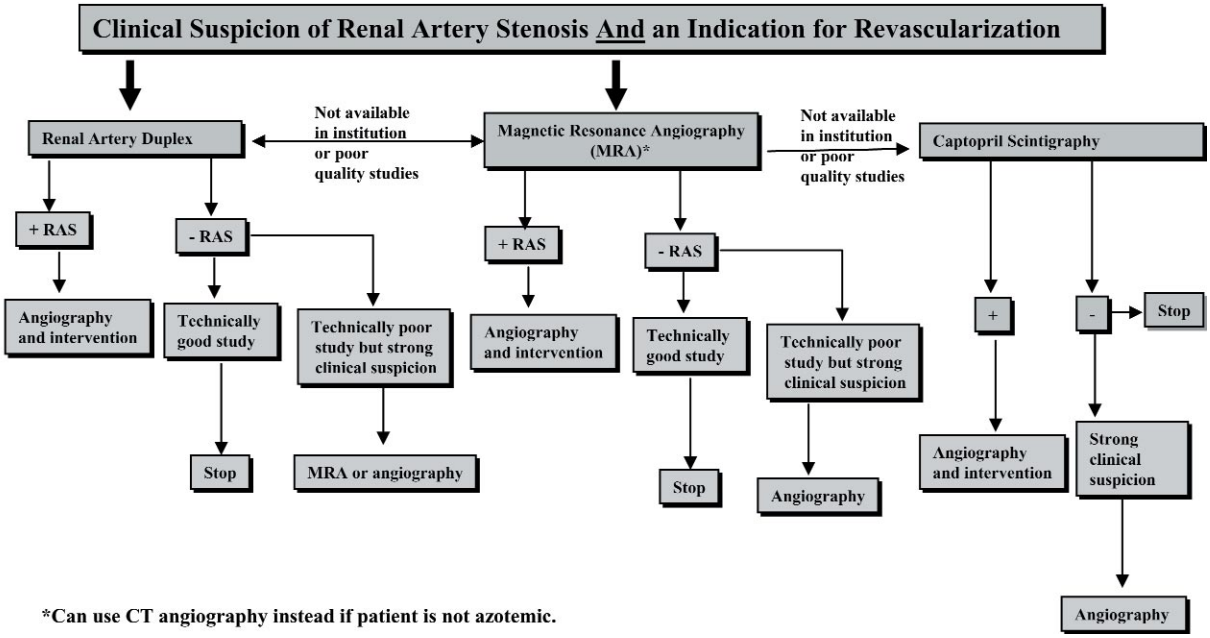

Fig. 2. Algorithm for the diagnosis of renal artery stenosis. Adapted with permission from Carman T, Olin JW. Diagnosis of renal artery stenosis: what is the optimal diagnostic test? Curr Interv Cardiol Rep 2000; 2:116 (43).

types of intervention. A comprehensive risk factor reduction program should be undertaken. Antiplatelet agents should be prescribed to help lower the extremely high cardiovascular morbidity and mortality that occurs in this patient population. Many patients have superimposed essential hypertension and will still require lifelong antihypertensive therapy even after revascularization of the renal arteries.

Patients with RAS who are treated solely with medical therapy should be carefully followed for progression of disease. Renal function should be evaluated every three months, along with periodic serial duplex ultrasound imaging.

Percutaneous Transluminal Angioplasty

Percutaneous transluminal angioplasty (PTA) is the treatment of choice for patients with FMD. However, since most patients with atherosclerotic RAS have ostial or proximal disease, the preferred endovascular therapy utilizes stent implantation. While blood pressure control and preservation of renal function may occur, the restenosis rate is extraordinarily high with angioplasty alone (51).

There have been three randomized prospective trials comparing medical management to angioplasty for blood pressure control in patients with atherosclerotic RAS (52–54). Each of the three studies has significant drawbacks precluding any definite conclusions. In the prospective study published by van Jaarsveld et al. (54), 106 patients with angiographically documented RAS were randomly assigned to PTA or medical therapy, and had blood pressure and renal function assessed at 3 and 12 months. Baseline blood pressure was 179/104 mm Hg and 180/103 mm Hg in the angioplasty and drug therapy groups respectively. At 3 and 12 months, there was no significant difference in the degree to which blood pressure was controlled between the two groups, but the extent and dose of antihypertensive medications was lowered in the PTA group. Unfortunately, there were several rather serious problems that make interpretation of the results difficult (55). For example, 44% of patients randomized to medical therapy crossed over to the balloon angioplasty group, resulting in dilution of the long-term outcome differences. In addition, there was a favorable trend to all primary outcome events, and with the small sample size, we calculated that the chance of a type II statistical error was substantial. Finally, the authors chose a 50% diameter reduction as the cut-off for "hemodynamically significant" renal artery lesions, despite the clear evidence that a lesion of at least 70% stenosis is required to cause significant hypertension or a decrement in renal function (3). Only 57% of the patients had stenosis of greater than 70%.

Renal Artery Stents

Due to the high restenosis rate with angioplasty alone, endovascular stents offer a significant advantage over PTA in patients with atherosclerotic disease, especially those with ostial stenosis. The degree of stenosis after stenting approaches zero, and most dissection flaps caused by PTA alone are successfully sealed with stents (Fig. 3) (9). However, despite the widespread use of stents in thousands of renal arteries since the late 1980s, there is still no Food and Drug Administration approval of these devices for the renal circulation.

For the best results, the shortest stent to adequately cover the lesion should be used. The stent must extend 1–2 mm into the aorta in patients with ostial disease and be fully expanded. Underdeployment of the stent is a common problem early in an operator's experience. It may be worthwhile to do the first several cases with intravascular ultrasound, to be certain the stent is adequately expanded. It is also important to make sure that no post-procedure pressure gradient exists.

White, Ramee and associates (56) evaluated the safety and efficacy of renal artery stent implantation in patients with lesions that did not respond well to angioplasty alone. Balloon expandable stents were placed in 100 consecutive patients (133 renal arteries). The technical success of the procedure was 99%. The mean blood pressure values were 173±25/88±17 mm Hg prior to stent implantation and 146±20/77±12 mm Hg six months after renal artery stenting ($p<0.01$). Angiographic follow-up with 67 patients (mean 8.7±5 months) demonstrated restenosis (RAS had exceeded 50%) in 15 patients (19%).

Blum et al. (6) prospectively placed a Palmaz stent in 68 patients (74 lesions) with ostial RAS and suboptimal PTA. Five-year patency was 84.5% (mean follow-up was 27 months). Restenosis occurred in 8 of 74 arteries (11%), but after reintervention the secondary 5-year patency rate was 92.4%. Blood pressure was cured or improved in 78% of patients. There was no significant change in the serum creatinine values after stent implantation.

A meta-analysis of 14 studies (678 patients) compared the technical success, clinical efficacy and restenosis rate after PTA and stent implantation (Table 5) (57).

The effect that renal artery stent implantation had on preserving renal function was studied in 2 small series (58, 59). Both studies used the reciprocal of the serum creatinine to determine the rate of decline or improvement in renal function. Harden et al. (58) placed renal artery stents in 32 patients (33 arteries) and reported that renal function improved or stabilized in 22 patients (69%). In 25 patients with complete follow-up, Watson and associates (59) demonstrated that after stent placement, the slopes of the reciprocal of the serum creatinine (1/Scr) were positive in 18 patients and less negative in 7 patients.

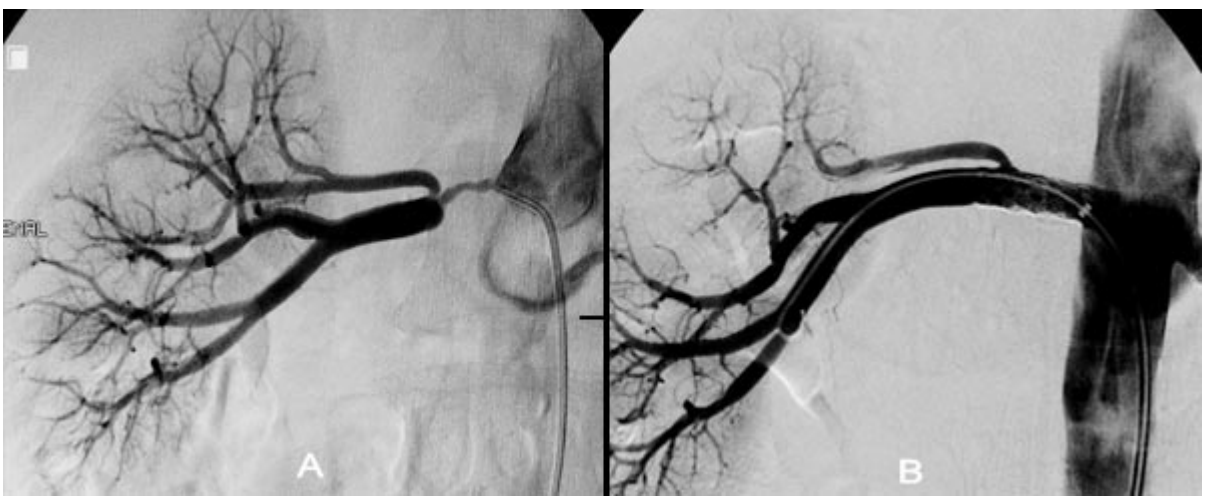

Fig. 3. A. Severe stenosis of the right renal artery beginning at its ostium and extending distally to a branch that supplies the upper pole of the kidney. **B.** Excellent angiographic result after stent placement. The smaller superior branch is still patent despite being covered by the stent (stent jail). Courtesy of J. Michael Bacharach, M.D., M.P.H. Reproduced with permission from Olin JW, Begelman SM. Renal artery disease. In: Topol E, editor. Textbook of cardiovascular medicine. 2nd ed. Philadelphia: Lippincott Raven; 2002. pp. 2149 (9).

TABLE 5
Clinical and Angiographic Follow-up in Patients Who Underwent Renal Artery Stent Placement

Study	No. Pts	Stent	Technical Success	Follow-up (months)	Hypertension		Renal Function		Restenosis	Complications
					Cure	Improved	Improved	Stable		
Wilms	11	Wallstent	83%	7	30%	40%	0%	0%	29%	3 (25%)
Kuhn	10	Strecker	80%	11	29%	43%	50%	NM	25%	4 (40%)
Ree	28	Palmaz	96%	7	11%	54%	36%	36%	39%	5 (18%)
Hennequin	21	Wallstent	100%	32	14%	86%	17%	50%	20%	4 (19%)
van de Ven	24	Palmaz	100%	6	68%	5%	36%	64%	13%	3 (11%)
Henry	59	Palmaz	100%	14	19%	57%	20%	NM	9%	2 (3%)
Iannone	63	Palmaz	99%	10	4%	35%	36%	45%	14%	11 (13%)
Blum	68	Palmaz	100%	27	16%	62%	NM	NM	11%	0 (0%)
Bosclair	33	Palmaz	100%	13	6%	61%	41%	35%	—	6 (17%)
Harden	32	Palmaz	100%	6	NM	NM	34%	34%	13%	1 (3%)
White	100	Palmaz	99%	6	NM	NM	20%	NM	19%	2 (2%)
Rundback	45	Palmaz	94%	17	NM	NM	NM	NM	25%	5 (9%)
Shannon	21	Palmaz	100%	9	NM	NM	43%	29%	0%	2 (9%)
Dorros	163	Palmaz	100%	48	3%	51%	NM	NM	—	23 (11%)
Total	678	…	98%*	16*	20%*	49%*	30%	38%	17%	11*

*Mean based on random-effects model
Reproduced with permission from Leertouwer TC, Gussenhoven EJ, Bosch JL, et al. Stent placement for renal arterial stenosis: where do we stand? A meta-analysis. Radiology 2000; 216:78–85 (57).

Complications of renal artery stent placement include access-related complications such as hematoma, retroperitoneal hemorrhage, pseudoaneurysm, arterio-venous fistula, vessel occlusion, and infection. However, the most serious complications result from atheromatous embolization to the kidneys, bowel and legs. Stent malposition and rupture of the renal artery are less common complications. The complication rate varies considerably between centers. High volume centers generally can perform renal artery stenting with minimal morbidity and mortality. Although all studies reported use of an antithrombotic agent during the procedure and most patients were discharged on an antiplatelet agent, the regimens varied.

There has been preliminary experience with emboli protection devices in Europe; clinical trials are just getting underway in the United States. When these devices are used, a wire is placed across the renal artery lesion and a balloon occlusion device or a filter device is deployed in the distal renal artery. The purpose of this is to capture the atherosclerotic debris caused by angioplasty and stenting, with a goal of preventing atheromatous embolization to the kidneys. Henry et al. used the PercuSurge™ GuardWire device on 32 arteries in 28 patients (60). The procedure was technically successful in all patients, and visible debris was recovered in all patients. Protected renal artery stenting is an exciting area for investigation to determine its efficacy.

Surgical Revascularization

Surgical revascularization plays a much smaller role than it had previously, due to the excellent technical results achievable with angioplasty and stent implantation. Many patients can now undergo renal artery stent implantation as an outpatient procedure, at a fraction of the cost of surgical revascularization.

Current indications for surgical revascularization include: branch disease from FMD that cannot be treated adequately with balloon angioplasty (4); recurrent stenosis after stenting (however, this has been extremely rare in our experience) (9); or simultaneous aortic surgery (abdominal aortic aneurysm repair or symptomatic aortoiliac disease). Even in this last circumstance, it may be advisable to stent the renal artery first and then proceed with aortic reconstruction. The mortality rate of aortic replacement and renal artery revascularization is higher than for either procedure alone (61).

The Role of Revascularization for Renal Salvage

Patients who are at a markedly increased risk of renal failure are those with greater than 70% bilateral RAS or severe stenosis to a single

functioning kidney. In this patient subgroup, the risk of total occlusion of the renal artery is significant, and if this occurs, the outcome is a critical decrease in functioning renal mass, with resulting renal failure (4, 45–47, 62–64).

Complete occlusion of the renal artery most often results in irreversible ischemic damage to the involved kidney. However, in some patients with gradual arterial occlusion, the viability of the kidney can be maintained through the development of collateral arterial supply (62, 64). There are certain clues that may help to predict renal salvageability in patients with an occluded renal artery:

- Angiographic demonstration of late filling of the distal renal arterial tree by collateral vessels on the side of total arterial occlusion (64)
- Renal size of 8–9 cm
- Function of the involved kidney on a renal flow scan
- The presence of a nephrogram after a contrast arteriogram
- A renal biopsy showing well-preserved glomeruli and an absence of significant glomerulosclerosis

There are reports showing that restoration of renal function in patients with totally occluded renal arteries is feasible with either endovascular therapy or surgical revascularization. Kaylor et al. (46) reported on 9 patients who were on dialysis secondary to atherosclerotic RAS for between one week and 13 months. Reversal of end-stage renal failure occurred in all 9 patients with surgical revascularization. The serum creatinine at one month ranged from 1.1–4.2 mg/dL (mean 2.5 mg/dL). Hansen and colleagues (47) have also shown that it is possible to restore renal function with surgical revascularization in some patients who have been on chronic hemodialysis therapy. From 1987–1993, 340 patients underwent surgical renal revascularization. Twenty patients were receiving hemodialysis before renal artery repair. Hemodialysis was discontinued in 16 of the 20 patients (80%). Two of the 16 patients resumed dialysis 4 and 6 months after surgery. The long-term survival was better for those who were dialysis independent than for those who required ongoing dialysis therapy. There were only 2 late deaths among the 14 patients not receiving dialysis, compared to 5 late deaths among the 6 patients who continued to receive dialysis after surgical revascularization ($p<0.01$).

The likelihood of improving renal function appears to be dependent on a relationship between the severity of stenosis of the main renal artery, the rapidity in the development of renal failure and the degree of parenchymal damage to the kidney. Several investigators have suggested that parenchyma damage may in fact be the most important determinant of non-reversibility of renal failure (12).

Revascularization for Control of Congestive Heart Failure or Flash Pulmonary Edema

The emerging indications for renal revascularization are CHF and flash pulmonary edema (10, 49, 65–67). Patients with these conditions most often have significant bilateral RAS or RAS to a solitary functioning kidney. The left ventricular systolic function may be normal or impaired and the blood pressure may be well controlled (10). We reported 39 patients who underwent renal artery stent implantation for control of CHF (10). This represented 19% of our renal artery stent population. In this series, 18 patients (46%) had bilateral RAS and 21 patients (54%) had stenosis to a solitary functioning kidney. Renal artery stent implantation was technically successful in all 39 patients. The blood pressure was improved in 72% of the patients. Renal function was improved in 51%, remained stable in 26% and deteriorated in 23%. The mean number of hospitalizations for CHF prior to stenting was 2.37±1.42 (range 1–6); after stenting it was 0.30±0.065 (range 0–3), $p<0.001$. Seventy-seven percent of the patients had no further hospitalizations after renal artery stenting, over a mean follow-up period of 21.3 months.

The mechanism by which RAS causes CHF and pulmonary edema is not well defined. The improvement after stenting may in part be related to the ability to use ACEIs, especially for those with impaired left ventricle function and the ability to better control volume.

The Future

Over the last decade, renal artery angioplasty and stenting has become much safer because of better equipment and more experienced operators. There are several important questions that need to be answered in the upcoming years:

- How can we more accurately predict which patients will respond favorably after revascularization and which patients will not?
- Will emboli protection devices prevent the worsening in renal function that occurs in some patients after renal intervention?

- Will drug eluting stents prevent restenosis in the 15–20% of patients who demonstrate evidence of restenosis?
- Why is the survival rate so poor for patients who have atherosclerotic renal artery stenosis? Will renal revascularization improve the survival rate? Will a more comprehensive risk factor reduction strategy lower mortality?
- What is the mechanism of CHF in patients with bilateral disease or disease in a single functioning kidney?

References

1. Olin JW, Melia M, Young JR, et al. Prevalence of atherosclerotic renal artery stenosis in patients with atherosclerosis elsewhere. Am J Med 1990; 88:46N–51N.
2. Harding MB, Smith LR, Himmelstein SI, et al. Renal artery stenosis: prevalence and associated risk factors in patients undergoing routine cardiac catheterization. J Am Soc Nephrol 1992; 2:1608–1616.
3. Safian RD, Textor SC. Renal-artery stenosis. N Engl J Med 2001; 344:431–442.
4. Novick AC, Ziegelbaum M, Vidt DG, et al. Trends in surgical revascularization for renal artery disease. Ten years' experience. JAMA 1987; 257:498–501.
5. Dustan HP, Humphries AW, De Wolfe VG, et al. Normal arterial pressure in patients with renal arterial stenosis. JAMA 1964; 187:1028–1029.
6. Blum U, Krumme B, Flugel P, et al. Treatment of ostial renal-artery stenosis with vascular endoprostheses after unsuccessful balloon angioplasty. N Engl J Med 1997; 336:459–465.
7. Dorros G, Jaff M, Mathiak L, et al. Four-year follow-up of Palmaz-Schatz stent revascularization as treatment for atherosclerotic renal artery stenosis. Circulation 1998; 98:642–647.
8. Rimmer J, Gennari FJ. Atherosclerotic renovascular disease and progressive renal failure. Ann Intern Med 1993; 118:712–719.
9. Olin JW, Begelman SM. Renal artery disease. In: Topol E, editor. Textbook of cardiovascular medicine. 2nd ed. Philadelphia: Lippincott Raven; 2002. pp. 2139–2159.
10. Gray BH, Olin JW, Childs MB, et al. Clinical benefit of renal artery angioplasty with stenting for the control of recurrent and refractory congestive heart failure. Vasc Med 2003; 17:275–279.
11. Wright J, Shurrab AE, Cheung C, et al. A prospective study of the determinants of renal functional outcome and mortality in atherosclerotic renovascular disease. Am J Kidney Dis 2002; 39:1153–1161.
12. Textor SC, Wilcox C. Ischemic nephropathy/azotemic renovascular disease. Semin Nephrol 2000; 20:489–502.
13. Textor SC, Tarazi RC, Novick AC, et al. Regulation of renal hemodynamics and glomerular filtration rate in patients with renovascular hypertension during converting enzyme inhibition with captopril. Am J Med 1984; 76(5B):29–37.
14. Silas JH, Klenka Z, Solomon SA, Bone JM. Captopril induced reversible renal failure: a marker for renal artery stenosis affecting a solitary kidney. Br Med J (Clin Res Ed) 1983; 286:1702–1703.
15. Jacobson HR. Ischemic renal disease: an overlooked clinical entity? Kidney Int 1988; 34:729–743.
16. Packer M, Lee WH, Medina N, et al. Functional renal insufficiency during long-term therapy with captopril and enalapril in severe congestive heart failure. Ann Intern Med 1987; 106:346–354.
17. Textor SC. Renal failure related to angiotensin-converting enzyme inhibitors. Semin Nephrol 1997; 17:67–76.
18. Watson ML, Bell GM, Muir AL, et al. Captopril/diuretic combinations in severe renovascular disease: a cautionary note. Lancet 1983; 2:404–405.
19. Hricik D, Browning PJ, Kopelman R, et al. Captopril-induced functional renal insufficiency in patients with bilateral renal-artery stenosis or renal-artery stenosis to a solitary kidney. N Engl J Med 1983; 308:373–376.
20. Hansen KJ, Edwards MS, Craven TE, et al. Prevalence of renovascular disease in the elderly: a population-based study. J Vasc Surg 2002; 36:443–451.
21. Scoble JE. The epidemiology and clinical manifestations of atherosclerotic renal disease. In: Novick AC, Scoble J, Hamilton G, editors. Renal vascular disease. London: WB Saunders Co., Ltd.; 1996. pp. 303–314.
22. Conlon PJ, Little MA, Pieper K, Mark DB. Severity of renal vascular disease predicts mortality in patients undergoing coronary angiography. Kidney Int 2001; 60:1490–1497.
23. Rihal CS, Textor SC, Breen JF, et al. Incidental renal artery stenosis among a prospective cohort of hypertensive patients undergoing coronary angiography. Mayo Clin Proc 2002; 77:309–316.
24. Schreiber MJ, Pohl MA, Novick AC. The natural history of atherosclerotic and fibrous renal artery disease. Urol Clin North Am 1984; 11:383–392.
25. Zierler RE, Bergelin RO, Davidson RC, et al. A prospective study of disease progression in patients with atherosclerotic renal artery stenosis. Am J Hypertens 1996; 9:1055–1061.
26. Caps MT, Zierler RE, Polissar NL, et al. Risk of atrophy in kidneys with atherosclerotic renal artery stenosis. Kidney Int 1998; 53:735–742.
27. Scoble JE, Maher ER, Hamilton G, et al. Atherosclerotic renovascular disease causing renal impairment — a case for treatment. Clin Nephrol 1989; 31:119–122.
28. Mailloux LU, Napolitano B, Bellucci AG, et al. Renal vascular disease causing end-stage renal disease, incidence, clinical correlates, and outcomes: a 20-year clinical experience. Am J Kidney Dis 1994; 24:622–629.
29. Conlon PJ, O'Riordan E, Kalra P. New insights into the epidemiologic and clinical manifestations of atherosclerotic renovascular disease. Am J Kidney Dis 2000; 35:573–587.
30. The Sixth Report of the Joint National Committee on Prevention, Detection, Evaluation, and Treatment of High Blood Pressure. Arch Intern Med 1997; 157(21):2413–2446.
31. Gifford RW Jr, McCormack LJ, Poutasse EF. The atrophic kidney: its role in hypertension. Mayo Clin Proc 1965; 40:834–852.
32. Carman T, Olin JW, Czum J. Noninvasive imaging of renal arteries. Urol Clin North Am 2001; 28:815–826.
33. Prince MR. Renal MR angiography: a comprehensive approach. J Magn Reson Imaging 1998; 8:511–516.
34. Stack R. Renal artery stenosis — under-diagnosed and under-treated in the cardiac patient. J Invasive Cardiol 1999; 11:103–106.
35. White CJ. The renal oculosten(t)otic reflex. Catheter Cardiovasc Diagn 1996; 37:251.
36. Radermacher J, Chavan A, Bleck J, et al. Use of Doppler ultrasonography to predict the outcome of therapy for renal artery stenosis. N Engl J Med 2001; 344:410–417.
37. Olin JW, Piedmonte MR, Young JR, et al. The utility of duplex ultrasound scanning of the renal arteries for diagnosing significant renal artery stenosis. Ann Intern Med 1995; 122:833–838.
38. Saloner D. Determinants of image appearance in contrast-enhanced magnetic resonance angiography: a review. Invest Radiol 1998; 33:488–495.

39. Leung DA, Hoffman U, Pfammatter T, et al. Magnetic resonance angiography versus duplex sonography for diagnosing renovascular disease. Hypertension 1999; 33:726–731.
40. Loubeyre P, Trolliet P, Cahen R, et al. MR angiography of renal artery stenosis: value of the combination of three-dimensional time-of-flight and three-dimensional phase-contrast MR angiography sequences. AJR Am J Roentgenol 1996; 167:489–494.
41. Tan KT, van Beek EJ, Brown PW, et al. Magnetic resonance angiography for the diagnosis of renal artery stenosis: a meta-analysis. Clin Radiol 2002; 57:617–624.
42. Nally JV, Clarke HS Jr, Grecos GP, et al. Effect of captopril on 99mTc-diethylenetriaminepentaacetic acid renograms in two-kidney, one clip hypertension. Hypertension 1986; 8:685–693.
43. Carman T, Olin JW. Diagnosis of renal artery stenosis: what is the optimal test? Curr Interv Cardiol Report 2000; 2:111–118.
44. Jaff MR, Olin JW. Atherosclerotic stenosis of the renal arteries. Indications for intervention. Tex Heart Inst J 1998; 25:34–39.
45. Novick AC, Textor SC, Bodie B, et al. Revascularization to preserve renal function in patients with atherosclerotic renovascular disease. Urol Clin North Am 1984; 11:477–490.
46. Kaylor WM, Novick AC, Ziegelbaum M, Vidt DG. Reversal of end stage renal failure with surgical revascularization in patients with atherosclerotic renal artery occlusion. J Urol 1989; 141:486–488.
47. Hansen KJ, Thomason RB, Craven TE, et al. Surgical management of dialysis-dependent ischemic nephropathy. J Vasc Surg 1995; 21:197–209.
48. Olin JW, Harjai K, Graor RA. Recurrent pulmonary edema in a patient with atherosclerotic renal artery stenosis. J Vasc Med Biol 1993; 4:216–220.
49. Pickering TG, Herman L, Devereux RB, et al. Recurrent pulmonary oedema in hypertension due to bilateral renal artery stenosis: treatment by angioplasty or surgical revascularisation. Lancet 1988; 2(8610):551–552.
50. Bloch MJ, Trost DW, Pickering TG, et al. Prevention of recurrent pulmonary edema in patients with bilateral renovascular disease through renal artery stent placement. Am J Hypertens 1999; 12(1 Pt 1):1–7.
51. Ramsay LE, Waller PC. Blood pressure response to percutaneous transluminal angioplasty for renovascular hypertension: an overview of published series. BMJ 1990; 300:569–572.
52. Plouin PF, Chatellier G, Darne B, Raynaud A. Blood pressure outcome of angioplasty in atherosclerotic renal artery stenosis: a randomized trial. Essai Multicentrique Medicaments vs Angioplastie (EMMA) Study Group. Hypertension 1998; 31:823–829.
53. Webster J, Marshall F, Abdalla M, et al. Randomised comparison of percutaneous angioplasty vs continued medical therapy for hypertensive patients with atheromatous renal artery stenosis. Scottish and Newcastle Renal Artery Stenosis Collaborative Group. J Hum Hypertens 1998; 12:329–335.
54. van Jaarsveld BC, Krijnen P, Pieterman H, et al. The effect of balloon angioplasty on hypertension in atherosclerotic renal-artery stenosis. Dutch Renal Artery Stenosis Intervention Cooperative Study Group. N Engl J Med 2000; 342:1007–1014.
55. Tan WA, Wholey MH, Olin JW. Renal angioplasty and hypertension [letter]. N Engl J Med 2000; 343:438.
56. White CJ, Ramee SR, Collins TJ, et al. Renal artery stent placement: utility in lesions difficult to treat with balloon angioplasty. J Am Coll Cardiol 1997; 30:1445–1450.
57. Leertouwer TC, Gussenhoven EJ, Bosch JL, et al. Stent placement for renal arterial stenosis: where do we stand? A meta-analysis. Radiology 2000; 216:78–85.
58. Harden PN, MacLeod MJ, Rodger RS, et al. Effect of renal-artery stenting on progression of renovascular renal failure. Lancet 1997; 349:1113–1136.
59. Watson PS, Hadjipetrou P, Cox SV, et al. Effect of renal artery stenting on renal function and size in patients with atherosclerotic renovascular disease. Circulation 2000; 102:1671–1677.
60. Henry M, Klonaris C, Henry I, et al. Protected renal stenting with the PercuSurge GuardWire device: a pilot study. J Endovasc Ther 2001; 8:227–237.
61. Tarazi RY, Hertzer NR, Beven EG, et al. Simultaneous aortic reconstruction and renal revascularization: risk factors and late results in eighty-nine patients. J Vasc Surg 1987; 5:707–714.
62. Zinman L, Libertino JA. Revascularization of the chronic totally occluded renal artery with restoration of renal function. J Urol 1977; 18:517–521.
63. Schefft P, Novick AC, Stewart BH, Straffon RA. Renal revascularization in patients with total occlusion of the renal artery. J Urol 1980; 1 24:184–186.
64. Olin JW, Graor RA, Young JR. Thrombolytic therapy for renal artery occlusions: a preliminary report. Cleve Clin J Med 1989; 56:432–438.
65. Diamond JR. Flash pulmonary edema and the diagnostic suspicion of occult renal artery stenosis. Am J Kidney Dis 1993; 21:328–330.
66. Messina LM, Zelenock GB, Yao KA, Stanley JC. Renal revascularization for recurrent pulmonary edema in patients with poorly controlled hypertension and renal insufficiency: a distinct subgroup of patients with atherosclerotic renal artery occlusive disease. J Vasc Surg 1992; 15:73–80.
67. Pickering TG, Herman L, Devereux RB, et al. Recurrent pulmonary oedema in hypertension due to bilateral renal artery stenosis: treatment by angioplasty or surgical revascularization. Lancet 1988; 2:551–552.